

# Correlation of the AACD Accreditation Criteria and the Human Biologic Model

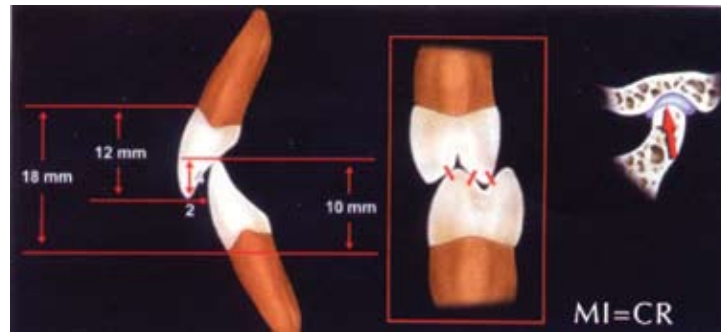

by  
Kenley Hunt, D.D.S.  
Mitch Turk, D.D.S.

*Dr. Hunt is a graduate of the Fairleigh Dickinson University School of Dentistry, and of the Lee Institute. He is a faculty member of the Orognathic Bioesthetics International, Inc. ([www.bioesthetics.com](http://www.bioesthetics.com)), a visiting professor at the University of California at Los Angeles, serves on the advisory board of the Institute of Dental Implant Awareness, and maintains a general practice with emphasis on esthetic dentistry in Brea, California.*

*Dr. Hunt lectures internationally and is a published author. He is an Accredited member of and an Accreditation examiner for the AACD and has served on the editorial review board of The Journal of Cosmetic Dentistry. Dr. Hunt can be reached at [kenleyhunt@prodigy.net](mailto:kenleyhunt@prodigy.net).*

*Dr. Turk is a graduate of the University of Southern California School of Dentistry, and the Lee Institute. He is a Master of the Academy of General Dentistry and a member of the AACD. Dr. Turk is a faculty member of Orognathic Bioesthetics International, Inc., and maintains a general practice with emphasis on esthetic dentistry and TMJ treatment in Orange, California. He can be reached at [gmturk@mouthdoc.com](mailto:gmturk@mouthdoc.com).*



**Figure 1: When the condyles are in centric relation, all teeth occlude evenly in the intercuspal position. When occlusal contacts are uneven, posterior occlusal interferences in lateral border jaw movements and avoidance patterns will develop.**

*(Reprinted with permission from Pract Periodont Aesthet Dent)<sup>8</sup>*

## ABSTRACT

To rehabilitate or enhance a human dentition, a healthy model is required for comparison. The American Academy of Cosmetic Dentistry (AACD) has set forth biologic, functional, and biomechanical standards to follow in patient treatment in esthetic dentistry. The purpose of this article is to correlate the AACD requisites with the practice of esthetic dentistry. Hard and soft tissues at their unworn optimal health serve as the human biologic model (HBM) to adhere to the AACD standards and to fulfill the patient and clinician expectations.

Three factors influence the formation of a healthy human dentition: heredity, environment, and function. By evaluating teeth as a part of an attractive functioning craniofacial structure of the human body, the clinician can arrive at the restoration or enhancement of any particular patient. This article presents such analysis of smile, midline, axial inclination, incisal embrasures, principles of proportion and central dominance, incisal edge positions, labial anatomy, and buccal corridor.

The authors hope that it will serve as a point of reference in the esthetic clinician's library.

---

*The selection of the model used in this article is based on the maximum health of the human masticatory system (i.e., healthy soft tissues, osseous structures, neuromuscular system, and dentition).*

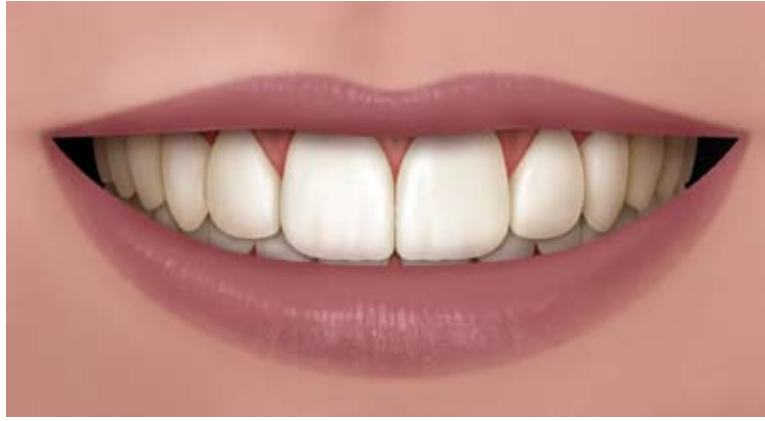---

## IMPORTANCE OF OCCLUSION IN COSMETIC DENTISTRY

The American Academy of Cosmetic Dentistry (AACD) has gone to great lengths to develop the Accreditation criteria for esthetic dentistry. The standards they have set forth are presented in *Diagnosis and Treatment Evaluation in Cosmetic Dentistry: A Guide to Accreditation Criteria*.<sup>1</sup> A dentist beginning the Accreditation process may ask: Why do I have to follow these criteria? What basis does the AACD have to substantiate that these criteria are a valid approach to esthetic form? It is the purpose of this article to explain, from biologic,

functional, and biomechanical perspectives, why the Academy has chosen the criteria used in the Accreditation Guide. It is not the purpose of this article to delve into anthropological and evolutionary science, but to accept the current condition of the species of man and observe the correlation between the biologic systems and cellular components that must accommodate the demands of the masticatory forces and the esthetic appearance of the dentition.

The evolutionary process of nature developed a capability for the human to compete and survive as a biologic organism. This capability includes the process of mastication (chewing) in order to prepare food for digestion and sustenance of life. All biologic life forms adhere to the physical laws of nature. It is the law of conservation of energy that dictates—from an efficiency perspective—that the strongest of the species are also the most efficient in energy consumption when performing a specific task, whether it is a lion hunting; or the masticating, swallowing, or speaking movements of man.



*Figure 2: The incisal length that is ideal for the maxillary central incisors has traditionally been influenced by the smile line and incisal display.<sup>1</sup>*

To evaluate these specific criteria in humans, a model is required for comparison. For the purpose of this article the human biological model (HBM) is used. The selection of the model used in this article is based on the maximum health of the human masticatory system (i.e., healthy soft tissues, osseous structures, neuromuscular system, and dentition). The dentition is supported by a healthy bone structure, and healthy gingival tissues seal the vascular supply and osseous tissues from the external environment. An unworn genetic form of the teeth is maximally efficient in incising and grinding the bolus of food before they are swallowed; it requires only a minimal amount of energy expended by the musculature.

---

*Bioesthetics is not a technique but rather an observation and application of the attributes of long-lasting dentitions found in healthy individuals.*

---

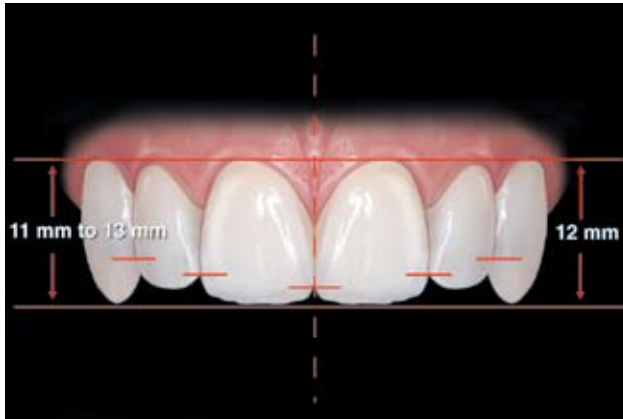
One of the first clinicians to study a system of dental health was Dr. Robert Lee, in 1982.<sup>2</sup> A dentist and a biologist, Lee examined, observed, and measured healthy human denti-

tion and soft tissues that showed little or no wear, in people over the age of 30. He noted that such near-perfect natural oral environments not only exist and function, but that they also are esthetically attractive (i.e., *beautiful*). Each tooth has a specific natural form for a specific function. In 1990, Lee completed his work about bioesthetics, and published the findings in Rufenacht's *Fundamentals of Esthetics*.<sup>3</sup> "Bioesthetics studies the beauty of living things in their natural forms and functions," states Lee. Bioesthetics examines the interrelationship of the three complexes—dental, dentofacial, and facial—in order to transform functional and esthetic oral defects into a naturally functioning and esthetic whole. Bioesthetics is not a technique but rather an observation and application of the attributes of long-lasting dentitions found in healthy individuals.

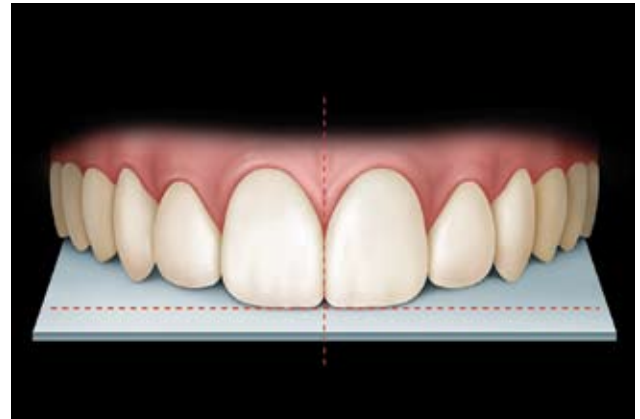
From Lee's observations of hard and soft tissues at their unworn optimal health, an ideal biologic form for the human dentition—the HBM—can be established. The model, so simple, yet of such a presence, has existed from the beginning of mankind. By studying this

model we discover how the system functions with maximization of the anterior guidance, verticalization of the posterior segment, and a stable physiologic position of the condyles in centric relation (CR) (Fig 1). Such anterior guidance allows the retention or creation of more natural (i.e., sharper) posterior crown forms without eccentric occlusal interferences, thereby minimizing the influence of condylar guidance on the morphology of the posterior teeth.

A thorough knowledge of occlusion is vitally important to clinicians practicing cosmetic dentistry. A cosmetic dentist must understand how the ideal biologic human dental system works. Implementing the observations of the HBM<sup>4</sup> allows the clinician to provide restorative care that is comfortable, long-lasting, functional, and esthetic.<sup>5-10</sup> The success of such comprehensive dentistry depends on the clinician's understanding of the morphology of natural dentition, including tooth position, temporomandibular joint (TMJ), and gingival contours; and the influence of these elements on the dental, dentofacial, and facial complexes.<sup>2,3</sup> It is not by examining the teeth as isolated components



**Figure 3:** Position of the maxillary central incisors and canines. Note that the lateral incisors are slightly shorter cervically and incisally.<sup>8</sup>



**Figure 4:** Minor discrepancies between facial and dental midlines are acceptable and in many instances not even noticeable.<sup>1</sup>

of the masticatory system, but by evaluating their role as part of a whole system that one can truly understand why teeth have a particular form and how that form is dictated by the interaction of tooth-against-tooth and tooth-against-soft tissue in mastication, speech, swallowing, and stabilization of the craniofacial system. This ideal form, in turn, sets the foundation for an esthetic exhibit of the natural anatomy of the teeth (smile) and establishes a pleasing proportion for the entire face. These are important social attributes to attract or convey messages to other members of the species.

In 1959, D'Amico published an article on the normal function of teeth, in which he states: "We cannot belittle the importance of the morphological characteristics of the teeth, their supporting structures, and their opposing functional relationship. The normal physiologic function and relation of all oral tissues is dependent primarily on such relationship."<sup>11</sup>

D'Amico continues: "I have tried to interpret and apply in dentistry certain aspects of physical changes in the natural normal functional relation as nature has intended them

to be. There is no doubt in my mind that the basic principles (forming the foundation) of past and present theories have been the outgrowth of what many have seen in the primitive or prehistoric man—the edge-to-edge bite of the incisors, and the lateral movements of the mandible. I have tried to present sufficient evidence to prove that this phenomenon is the result of function and various usages of the natural teeth."<sup>11</sup>

#### ANALYSIS OF THE SPECIFIC ATTRIBUTES OF THE AACD CRITERIA AND HUMAN BIOLOGIC MODEL

##### SMILE LINE

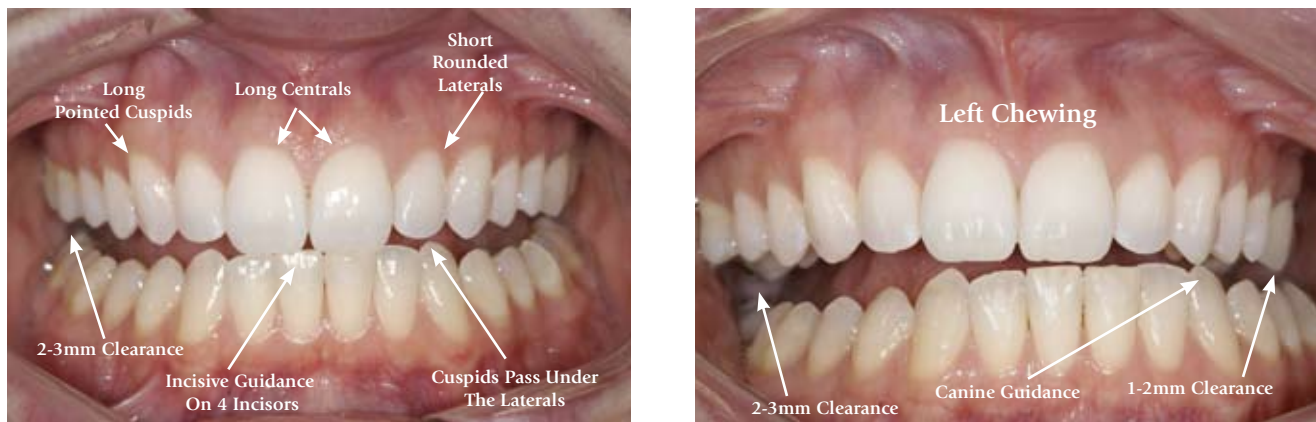
The *AACD Accreditation Guide* states: "The smile line (Fig 2) refers to an imaginary line along the incisal edges of the maxillary anterior teeth, which should mimic the curvature of the superior border of the lower lip while smiling. Another frame of reference for the smile line suggests that the centrals should appear slightly longer or, at the very least, not any shorter than the canines along the incisal plane" (Fig 2).<sup>1</sup>

According to the HBM, the lengths of the maxillary central incisors in a healthy and attractive human mouth are found to be approximately 12 mm for the maxillary canines, 10 mm for the mandibular central and lateral incisors, and 12 mm for the mandibular canines (Fig 3).<sup>12,13</sup> The length of the maxillary lateral incisors is somewhat shorter than that of the central incisors to allow the mandibular canines to pass freely during the incisive movements (Fig 3).

##### MIDLINE

As stated in the *AACD Guide*, the term "midline" refers to the vertical contact interface between two maxillary centrals (Fig 4).<sup>1</sup> As dictated by the HBM, the midline should be perpendicular to the incisal plane and parallel to the midline of the face (Fig 4).<sup>1</sup>

As shown in Figure 3, there must be harmony in the entire anterior complex, involving the gingival component, axial inclination, and the midline of the central incisors. The eyes, commissural line, or facial contour should never be used to establish the horizontal plane. With the patient's head perfectly erect, the maxillary canine incisal line is posi-



**Figures 5 and 6: Ideal morphology of the maxillary and mandibular natural anterior dentition.**

tioned parallel to the horizon and the midline of the central incisors, perpendicular to that plane.<sup>14</sup>

This alignment is critical from a functional aspect. The midline and horizontal plane relationship sets the stage for incisal and canine guidance. When the mandible moves forward to perform the incisive function, the edge-to-edge contact of the maxillary central incisors is on the four mandibular incisors (Fig 5). If the maxillary occlusal plane is not parallel to the horizon in conjunction with the mandible, an even contact with the lower incisors is not possible. The same principle applies to the chewing guidance (canine guidance): If the maxillary and mandibular planes are not parallel, interferences from chewing and nonchewing (balancing) sides may occur (Fig 6). The midlines of the maxillary and mandibular anterior teeth should also be congruent; that is, coinciding at all points when superimposed. Any deviation of the lower incisor midline mesial or distal to the maxillary midline creates an increase in the horizontal overlap of one of the maxillary cuspids. This results in diminished canine guidance on that side and subsequent

posterior interferences in function or flat cusp forms on the nonchewing (balancing) side (Figs 5 & 6).

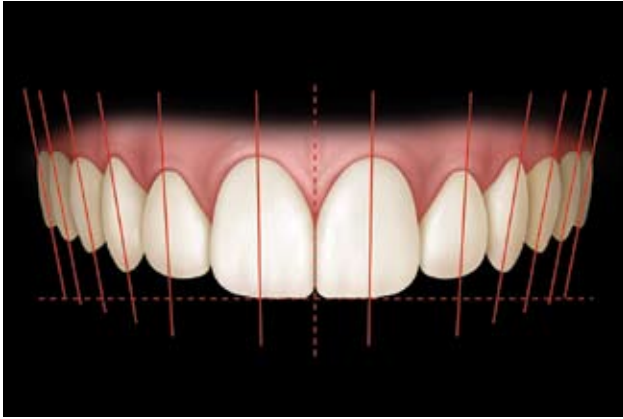
#### AXIAL INCLINATION

When analyzing the axial inclination from the perspective of the HBM, we must evaluate the dentition in three planes of space: X, Y, and Z (i.e., vertical, horizontal, and sagittal). These three planes must be evaluated with respect to the anterior and the posterior teeth, determining why these angulations promote healthy mastication without inflicting wear on the dentition.

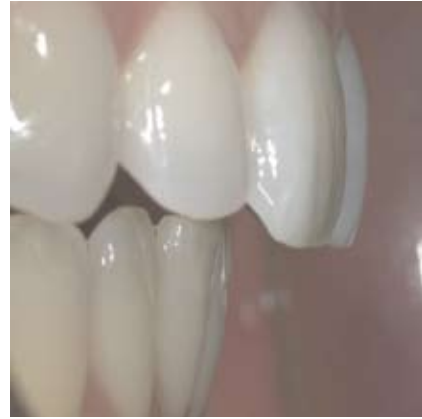It is stated in the *AACD Guide* that "The axial inclination compares the long axis alignment of the maxillary anterior teeth, as viewed at the smile line, to the vertical midline of the central incisors. From the central incisor to the canine, there should be a natural progressive increase in the mesial inclination of each subsequent anterior tooth" (Fig 7).<sup>1</sup>

This article will evaluate the teeth by first examining the anterior segment and then the posterior segment of the dentition. The horizontal plane to the midline of the maxillary anterior teeth has been discussed previously.

In the frontal plane, the anterior teeth are angled toward the midline in a mesial cant. This angulation allows compensation for the arch width difference between the maxillary and the mandibular teeth, permitting the correct anterior coupling of the incisors. The canted position also allows the central incisors to be positioned on all four lower incisors in incisive functions (Fig 5). The mesial cant of the canine positions the maxillary canine forward to engage the mandibular canine on the crest of the labial lobe to assist and maximize canine guidance. Canine guidance provides a continued separation of the posterior teeth in lateral closing movements of mastication. Only in the maximum intercuspation (MI) do the posterior teeth finally come into contact. Adequate incisive guidance should create at least 2 mm to 3 mm of clearance between the maxillary and the mandibular second molars when the maxillary and mandibular incisors are in an end-to-end position (Fig 5). Proper canine guidance should result in 1 mm to 2 mm of clearance of the upper and lower second molars on the chewing (working) side, and 2 mm to 3 mm of clearance of the same molars on



*Figure 7: Axial inclination can also refer to the degree of tipping in any plane of reference.<sup>1</sup>*



*Figure 8: This configuration of tooth arrangements results in the least amount of wear on teeth.*

the nonchewing (balancing) side (Fig 6). There are two reasons for the necessity of this clearance: efficient sharp cusp forms without interference in function, and physiologic flexure of the mandible under masticatory loads.

In the sagittal plane, the anterior dentition should cant labially at approximately 98° to 113° for the maxillary incisors and 85° to 104° for the mandibular incisors.<sup>15</sup> This labial cant allows the optimal anterior coupling of the maxillary and mandibular teeth in MI; and direction of compressive forces of the opposing incisors along the long axis of their roots during incisive actions, where this type of force is better tolerated by the osseous structures (Figs 1 & 8).<sup>3,16</sup> It is the very nature of shear forces on the maxillary central incisors during incisive movements that demands the greater cross-sectional area of their roots, and therefore the wider emergence profile of the crown of these incisors (Fig 8).<sup>16</sup>

Studying nature, several clinicians have noted the presence of cusps on the posterior adult teeth.<sup>3,4,17-</sup>

<sup>20</sup> In the frontal and sagittal plane, the angulations of the cusp tips of the teeth rise progressively in a

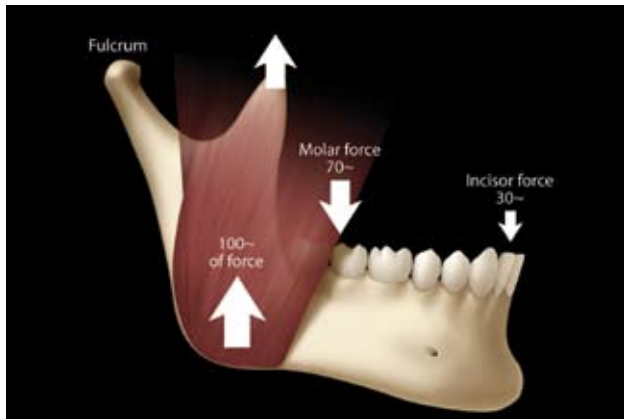
posterior direction (curve of Spee) (Fig 7). The crown-to-root ratio of the second molar becomes greater on the first molar and bicuspid, as we move mesially toward the canine. The second molar is closer to the fulcrum (the TMJ); consequently, the loads are greatest on the second molar (Fig 9).<sup>21</sup> This smaller crown-to-root ratio provides the design of the second molar to withstand increased loads. The entire system is protected by the position of the incisors at the end of a Class III lever, which provides a better leverage to control the effect of forces of the elevator muscles (Fig 9).<sup>22</sup>

In the frontal plane, the axial angulations of the buccal surfaces of the mandibular posterior teeth cant toward the lingual aspect (curve of Wilson). This buccolingual cant promotes posterior guidance. When there is a bolus of food on the chewing side, the guidance to closure takes place on the nonchewing side from the second molar forward (i.e., first molar, second premolar, first premolar, and the canine) (Fig 7).<sup>3,23</sup>

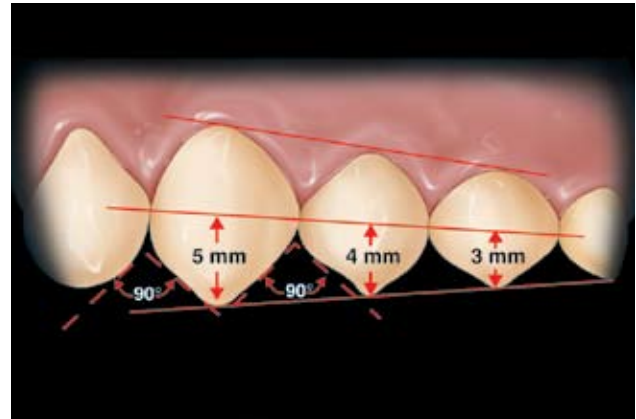
In the sagittal plane, the lengths of the buccal cusps of the maxillary canine, first premolar, second pre-

molar, and first molar ("first, second, third, and fourth canines"),<sup>3</sup> are approximately 5 mm, 4 mm, and 3 mm, respectively, when measured coronally from the interproximal contact points. Again, this sequencing of the teeth establishes posterior guidance. The mesial and distal embrasures of the canine usually are approximately at 90°. Moving in a posterior direction, lines connecting the maxillary cusp tips and the gingival marginal crests converge. The 90° embrasures allow space for more natural (sharper) cusp forms of the mandibular posterior teeth, developmentally and restoratively (Fig 10).<sup>3</sup>

The anterior and posterior teeth function in harmony to reduce and protect the masticatory system from functional overload.<sup>21</sup> In his work on anterior guidance, Williamson states that "...only when the posterior disclusion is obtained by an appropriate anterior guidance, can the elevating activity of the temporal and masseter muscles be reduced. It is not the contact of the canines that decreases the activity of the elevator muscles, but the elimination of posterior eccentric contacts."<sup>24</sup> The occlusal scheme is accomplished through



**Figure 9:** Anterior teeth have mechanical advantage over the posterior teeth because they are further away from the fulcrum.<sup>2</sup>



**Figure 10:** These gingivally placed marginal ridges create generous and beautiful natural buccal cusp forms, which are also functionally and esthetically compatible, with good anterior lengths and positions of the incisors.<sup>8</sup>

the proper axial inclination of the anterior teeth (Fig 1) and through the correct horizontal overlap of 1 mm to 2 mm and vertical overlap of 3 mm to 5 mm of the maxillary and mandibular central incisors.<sup>2-11</sup> This occlusal scheme facilitates the guidance of the posterior teeth with the condyles in centric relationship. These observations, obtained from studying the healthiest and finest of natural dentitions, are known as the principles of the Human Biologic Model;<sup>2-11</sup> that is, the TMJs seated in the socket, the anterior guidance, and genetic form of the teeth. When one understands the function, the esthetics will follow.

#### INCISAL EMBRASURES

To protect the extremely hard prismatic hydroxyapatite enamel from fracturing at the sharp incisal edges, cusp points, and ridges, nature has provided convexity at the crests and apexes of these tooth structures.<sup>2</sup> The *AACD Guide* states: "The incisal embrasures formed by these convexities should display a natural progressive increase in size or depth from the central to the mesial of the canine" (Figs 11 & 12).<sup>1</sup>

The incisal embrasure space between the maxillary central incisors is approximately 1 mm, the space between the central and lateral incisors 2 mm, and the space between lateral incisors and the canines approximately 3 mm (Fig 3).<sup>3</sup> This embrasure space is dictated in part by the morphology of the teeth. The shorter length of the lateral incisors precludes the incisal embrasure space being higher cervically than that of the central incisor. The disto-incisal curvature of the maxillary lateral incisor creates an open and cervically placed mesial embrasure space with the canine. The distal contact embrasure of the canine provides a high marginal ridge contact for the exceptionally large and sharp buccal cusp of the lower first premolar.

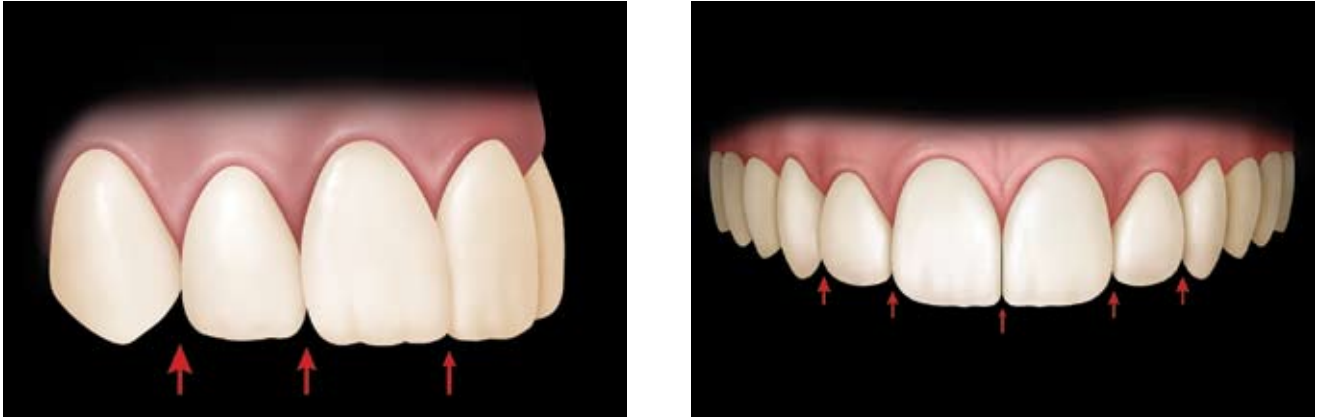
D'Amico states: "We have the interlocking relation of the maxillary canine between the mandibular canine and first premolar tooth. This is the most important articulation of the natural teeth, since it guides the mandible and the mandibular teeth into functional centric occlusion and serves to prevent the develop-

ment of any horizontal vectors on the incisors, premolars, and molars. It conforms to the natural laws governing the normal function of the entire masticatory apparatus; that is, the physiologic, biologic, and the physical laws governing the forces involved in its mechanics."<sup>25</sup> The HBM presents a standard of natural biomechanical excellence on which to base care of the human dental system (Fig 13).

#### PRINCIPLES OF PROPORTION AND CENTRAL DOMINANCE

"Central dominance," states the *AACD Guide*, "dictates that the maxillary central incisors must be the dominant teeth of the smile,<sup>26</sup> and they must display pleasing proportions (Fig 14). They are the key to the smile."<sup>71</sup>

As stated earlier, the width of the two maxillary central incisors is to provide maximum functional contact with the four mandibular incisors when the mandible moves forward in incisive guidance (Fig 5). Also, the length of approximately 12 mm (11 mm to 13 mm) should provide a separation of at least 2 mm



*Figures 11 and 12: The labial anatomy should mimic the morphology of the natural dentition. Note the presence of the lobes on the labial surface.<sup>1</sup>*

to 3 mm of clearance of the second molars (Fig 5).

In his 1959 article on natural teeth, D'Amico states: "By eliminating horizontal vectors, fatigue of the periodontium supporting the incisors, premolars, and molars is reduced to a minimum. The length of the central incisors consequently needs to be evaluated in relationship to the canine."<sup>11</sup>

After consideration of the functional requirements, what should the height-to-width proportion for the maxillary central incisors be? Much has been discussed with respect to the golden proportion with reference to the face, smile, and teeth. Is there a functional relationship or not? Huntley writes as follows: "We have suggested that Nature herself is familiar with the golden proportion and its near relative, the Fibonacci sequence, such as the genealogy of the drone bee, conifers, the shells of mollusk, and flowers. This view is difficult to reconcile with that of Sir James Jeans, who appeared to affirm that mathematics is indeed an externally existing body of knowledge, when he uttered his well-re-

membered aphorism that God is a mathematician. Therefore, the mathematical framework of beauty found in Nature may be invoked to supplement our anthology."<sup>27</sup>

Dr. Stephen Marquardt has quantified and constructed the archetypal or ideal form of the human face, in repose and in smiling configurations and expressions (for the frontal and lateral views of each expression).<sup>28</sup> He constructed these archetypal images using the geometric/mathematic configuration constructed from the Fibonacci set, specifically, the Decagon and Icosagon Matrices.<sup>28</sup> These matrices were used in multiple sets, sized at multiples of Phi and configured on the framework matrix. Each individual matrix contains the construction configuration of specific facial component (eye, nose, lips, etc.) or subcomponents (nasal tip, iris, etc.).<sup>28</sup>

Utilizing the mathematic progression of multiple Decagon and Icosagon Matrices, Marquardt states that the ideal configuration of the teeth, displayed during the normal attractive smile, also is a geometric construction.<sup>28</sup> He finds the geomet-

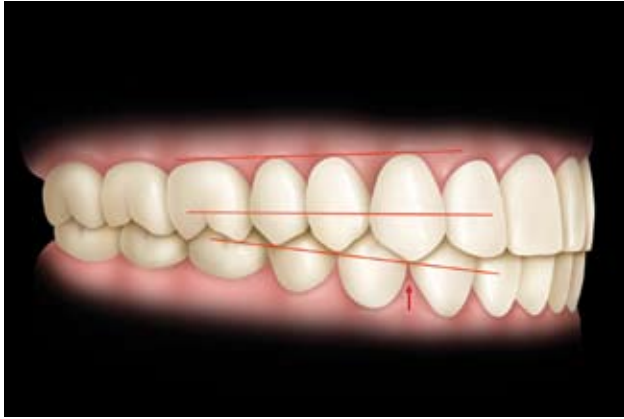
ric center of the smiling expression configuration to be the center of the embrasure between the two maxillary central incisors. This geometric center is the point from which all the maxillary teeth radiate laterally; it also is the geometric center of the lip lines, laugh lines, and dimples (if present).<sup>28</sup>

Per Marquardt, the position of the maxillary central incisors is set by radial intersects of the facial framework Decagon Matrix, the center of the central incisor embrasure being these intersects. The height of the centrals is equal to the Decagon Matrix height times Phi to the minus 6th; and the width of both centrals is equal to the Decagon Matrix height times Phi to the minus 5th.<sup>28</sup>

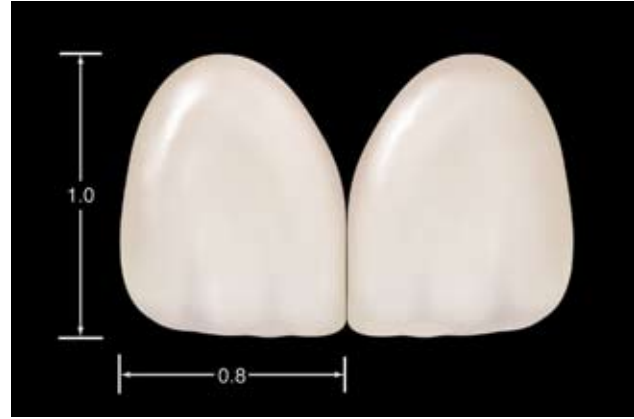#### INCISAL EDGE POSITIONS

When the AACD Accreditation criteria are compared to the HBM, they are congruent with respect to the incisal display and relationship of the incisal edge position to the horizontal plane (Fig 15). As mentioned previously, the incisal edge position of the maxillary lateral incisor is approximately 1 mm apical to





*Figure 13: The functional relation of the upper canines with the lower canines and first premolars eliminates the possibility of applying horizontal vectors to either upper or lower incisors, premolars, or molars during eccentric movements of the mandible.<sup>11</sup>*



*Figure 14: The principles of golden proportion suggest that the proportions of the centrals must be esthetic and mathematically correct. The width-to-length ratio of the centrals should be approximately 4:5 (0.8 to 1.0).<sup>1</sup>*

the incisal edges of the central incisor and canine. This position allows a maximum occlusal height of the mandibular canines, which maximizes anterior guidance; that is, the separation of the posterior teeth during right and left excursions.

*By understanding the HBM, the buccal corridor or the negative lateral space can create a pleasing transition from the teeth to the lips and the smile.*

#### LABIAL ANATOMY AND LINGUAL SURFACES

The *AACD Guide* directs attention to the labial anatomy by stating that “the labial anatomy should mimic the morphology of the natural dentition.”<sup>1</sup> In a natural form, lobes are formed on the labial surface of the anterior dentition. These lobes are important in esthetics because they control the reflection of light and add an illusion of width to the labial surface. In the HBM, the presence of the lobes varies from the indistinct to quite prominent; however, in ei-

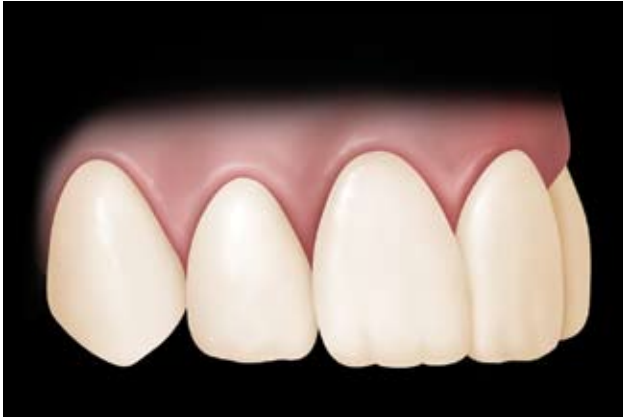ther case, these lobes are important to the buttressing of the thin incisal edges as they pierce the bolus of food.

The importance of the lingual convexities of the incisors cannot be ignored merely because they are hidden from the esthetic observer. Mesial and distal convex ridges of the maxillary incisors serve to strengthen the tooth against off-axis loads and allow minimal contacting surfaces of the opposing mandibular incisal edges. In his work on nature’s morphology, Kataoka states: “The mesial marginal ridge extends to the incisal edge, but the distal marginal ridge does not and is rather short in comparison to the mesial. This difference is the reason why the escape route of the lingual fossae is not present on the mesial aspect, but it is wide on the distal” (Fig 16).<sup>29</sup> Eccentric contacts occur on the mesial marginal ridge of the central and lateral incisors during incisive function and guidance.<sup>30</sup> This results in the efficiency of two sharp edges shearing the bolus of food between them. The lingual aspect of the maxillary incisors performs like a “plate,”

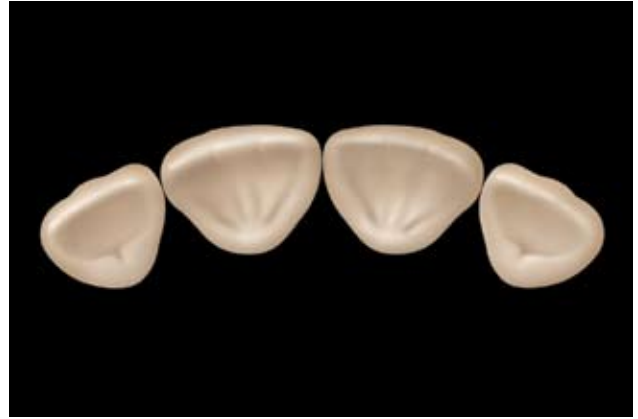and the lower incisors function as a “knife.” The prominent lingual lobe of the maxillary canine maximizes the canine guidance. As observed in the HBM, multiple contacts on the lingual surfaces of the maxillary incisors stabilize the teeth in the arch and allow smooth guiding planes during the closure into the CR position. These contacts, along with proper anterior length, permit not only separation of the posterior teeth through the anterior guidance, but also a proprioceptive anterior guidance. It is the proprioceptors in the periodontal ligament, lips, TMJ, tongue, cheeks, muscles, and the mechano-receptors in the pulp that relay information concerning spatial relation and touch of enamel surfaces to the central nervous system.<sup>31</sup> The resultant occluso-motor response lends confidence and control to the neuromuscular system, preventing pathologic wear, fracturing, and abracting of the enamel and root structures.

#### BUCCAL CORRIDOR

By understanding the HBM, the buccal corridor or the negative



*Figure 15: Note the open embrasures on the mesial and distal aspects of the lateral incisor.*



*Figure 16: The form of the lingual anatomy is important to provide proprioceptive contacts on convex surfaces for proper function and biomechanics.*

lateral space can create a pleasing transition from the teeth to the lips and the smile. However, the cosmetic dentist must understand the significance of the function of the teeth and the surrounding tissues to provide the appropriate appearance of the buccal corridor. The term “buccal corridor” identifies the dark space (negative space) visible during smile formation between the corners of the mouth and the buccal surfaces of the maxillary teeth.<sup>1</sup> Lee states that “the prerequisite of the front-back progression is the alignment of the outline or contour of the buccal surface, incisal third, median third, and, at a lower rate, the gingival third, as well as the alignment of the incisal mesio-buccal inclines.”<sup>3</sup>

The extent of the negative space is determined by the amount of contraction of the buccinator muscles pulling the cheeks away from the buccal surfaces of the posterior teeth (canines included), which are positioned in their neutral zone.<sup>32</sup> The negative lateral space is influenced by the silhouette existing between the maxillary labial and buccal sur-

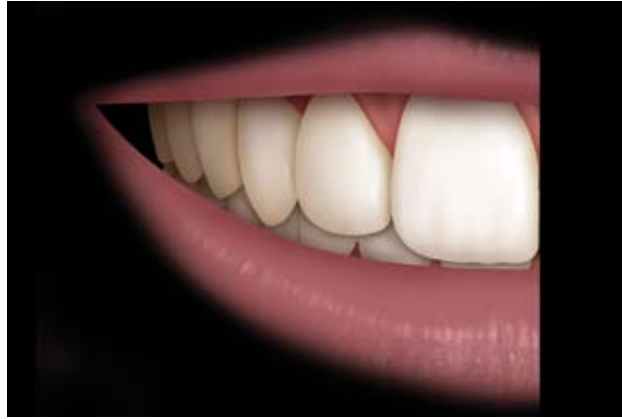face of the canine and posterior teeth and the width of the maxillary arch. The breadth of the smile depicts the buccal corridor as being properly treated (Fig 17). Let us analyze the buccal corridor from a functional aspect in three planes of space.

In the sagittal plane, the disto-incisal embrasure of the canine provides a high marginal ridge for the exceptionally large and sharp buccal cusp of the lower first premolar (Fig 13). The position of the maxillary arch toward the mandibular arch situates the teeth in the proper position for chewing. The maxillary arch and its posterior teeth are wider than the mandibular arch and its posterior teeth. This anatomic structure sets the stage for the posterior teeth to fulfill their main function of crushing the bolus of food. Examining this motion posteriorly, both buccal embrasures continue to rise posteriorly, enabling each succeeding sharp posterior cusp to fit into a high cervical marginal ridge. The morphology of the posterior teeth also contributes to this phenomenon. As already stated, the crown-

to-root ratio becomes smaller as the teeth are examined distally. In the horizontal and sagittal planes, the morphology of the posterior teeth becomes smaller when proceeding distally. This occurrence creates an occlusal-buccal plane, rising toward the Frankfort Plane as the teeth progress posteriorly (this plane is represented by a line connecting the cephalometric points of porion and orbitale). In the frontal plane, the axial angulations of the buccal surfaces of the posterior teeth in a gingival-occlusal direction cant toward the lingual aspect (curve of Wilson). This cant provides the proper silhouette for the negative lateral space (Fig 7).

#### MANDIBULAR TOOTH FORM

Figure 18 depicts the morphologic form of the mandibular teeth of the HBM. What is the functional and biologic rationale for this form? Note that the mandibular canines are slightly longer than the mandibular incisors. As discussed previously, the average length of the mandibular incisors is approximately 10 mm and of the mandibular canines approxi-



*Figure 17: The principles of gradation must be understood; this involves the perception of a progressive reduction of size from the most anterior to the most posterior teeth.<sup>1</sup>*

mately 12 mm (Fig 1). This greater length of the canines maximizes the anterior guidance, permitting the natural genetic tooth forms of the posterior teeth. The angulations of the mandibular teeth have also been previously discussed (Fig 8). The importance of these angulations and the length of the canines cannot be overemphasized. The morphology of the shorter maxillary lateral incisors allows the longer mandibular canines to pass through unimpeded in an incisive function. Again, the form of the dentition dictates the function (Fig 1). The incisal edges of the mandibular incisors are generally .5 mm wide, creating a sharp and efficient natural cutting tool.<sup>3</sup> The incisal corners of the mandibular incisors are slightly rounded for protection of the enamel rods. The embrasures are minimized, creating a wider masticatory blade.

## CONCLUSION

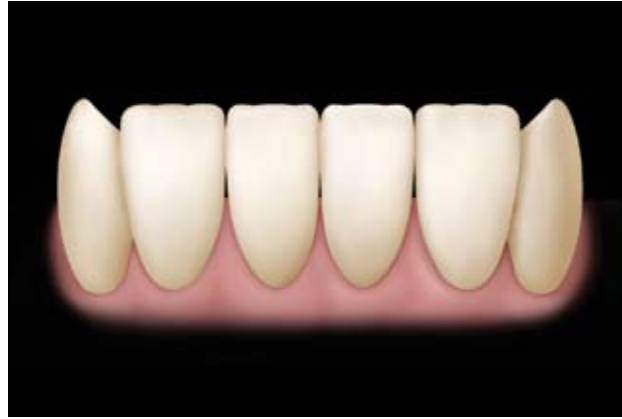Three basic factors influence the growth and development of an organism," states D'Amico.<sup>11</sup> They are heredity, environment, and function. Organic changes influenced

by heredity are the results of selection, arrangement, and mutation or regeneration of the genes within the chromosomes at the time of fertilization of the ovum by the sperm. In nature, environment supplies the natural foods to nourish the growing organism and provides the ways and means to protect the life of the organism from destruction by predators. The third factor—function—is quite important. In our particular field of bioesthetic dentistry, we have noted definite physical changes in the morphology of the natural teeth, musculature, and other tissues that are a part of and associated with the complete masticatory apparatus. These three basic factors control or influence the growth and development of the organism and are inseparable."<sup>11</sup>

D'Amico continues: "In the study of nature and the behavior of man we learn aberrations are the rule, not the exception. This rule holds true of humans: Fingerprints are an example; no two are alike. This rule also holds true in dentistry. We see deviations in the morphology of the teeth, their alignment, the position

in the dental arch, and in the growth and development of the maxilla and the mandible. The prime objective of any dental science should be the corrections of any deviations which tend to prevent normal development and function of the masticatory apparatus. If the average dentist, possessing average knowledge and skill, can conceptualize the ideal functional relation of the natural teeth, he will certainly be able to note serious deviations and proceed to make appropriate corrections. The objective of dental science and dental practice should be to preserve the natural teeth and prolong their normal function in the same ratio as medical science has prolonged the average span of human life. Anything less means that we have failed in meeting our obligations to mankind."<sup>11</sup>

The authors hope that this article on the importance of the human biologic model will be a useful adjunct to the *AACD Guide*; and will enhance the understanding, the knowledge, and the clinical practice of esthetic dentistry.



**Figure 18:** The masticator blade of the lower incisors functions as a knife shearing the bolus of food against the mesial marginal ridges of the maxillary central and lateral incisors (Fig 16). The thin convex incisal edges of the mandibular incisors function against convex surfaces of the mesial marginal ridges of the lingual surfaces of the maxillary incisors, both as proprioceptive contacts in closure and as cutting blades in shearing a bolus of food.

*Note:* The opinions expressed in this article are those of the author and do not necessarily represent those of the Academy.

*Author's Note:* Figures 2, 4, 7, 11, 12, 14-17 adapted with permission from AACD; illustrations® Dave Mazierski, 2005. Figures 9, 13, 18, illustrations® Dave Mazierski, 2005.

## References

- Blitz N, Steel C, Willhite C. *Diagnosis and Treatment Evaluation in Cosmetic Dentistry*. Madison, WI: AACD; 2001.
- Lee RL. Anterior guidance. In: Lundeen & Gibbs (eds.). *Advances in Occlusion* (Chapter 3). Boston: John Wright; 1982.
- Lee RL. Esthetics and its relationship to function. In: Rufenacht CR (ed.). *Fundamentals of Esthetics*. Carol Stream, IL: Quintessence; 1990.
- Dumont T. Clinical dentistry: Bioesthetics. *Private Pract* 2(8):1-3, 2002.
- Hunt K. Bioesthetics: The study of beauty in life. *Dent Today* 15:48-55, 1996.
- Hunt K. Bioesthetics: Working with nature to improve function and appearance. *The Journal of Cosmetic Dentistry*, 12(2):45-55, 1996.
- Hunt K. Bioesthetics: An interdisciplinary approach to improve function and appearance. *The Journal of Cosmetic Dentistry* (14)1:36-44, 1996.
- Hunt K. Full-mouth multidisciplinary restoration using the biological approach: A case report. *Pract Perio Aesthet Dent* 13(5):399-406, 2001.
- Hunt K. A full mouth rejuvenation using the biological approach: An 11-year case report follow-up. *Contemp Esthet Restor Pract* 6(6):26-37, 2002.
- Hunt K. The occlusal circle. *The Journal of Cosmetic Dentistry* 19(1):90-97, 2003.
- D'Amico A. The canine teeth: Normal functional relation of the natural teeth of man. *J So Calif Dent Assoc* 26:6-23,49-60,127-142,175-182,194-208,239-241, 1959.
- Liner HA. *Tooth Carving Manual*. New York: Columbia Dentoform Co. A Syntex Dental Co.; 1949.
- Magne P. Anatomical crown width/length ratios of unworn and worn maxillary teeth in white subjects. *J Prosthet Dent* 89(5):453-461, 2003.
- Lee RL. Standard head position and reference planes for dentofacial aesthetics. *Dent Today* 19(2):82-87, 2000.
- Graber TM. *Orthodontics Principles and Practice*. Philadelphia: W.B. Saunders; 1972.
- Misch CE. *Contemporary Implant Dentistry*. St. Louis, MO: Mosby; 1999.
- Renner RP. *An Introduction to Dental Anatomy and Esthetics*. Carol Stream, IL: Quintessence; 1985.
- Wheeler RC. *A Textbook of Dental Anatomy and Physiology* (2nd ed., pp. 130,148,161). Philadelphia: W.B. Saunders; 1954.
- Wheeler RC. *A Textbook of Dental Anatomy and Physiology* (6th ed., pp. 130,148,161). Philadelphia: W.B. Saunders; 1988.
- Stuart CE. Why dental restorations should have cusps. *J So Calif State Dent Assoc* 21:1998-2000, 1959.
- McNeill C. *Science and Practiced Occlusion*. Carol Stream, IL: Quintessence; 1997.
- Spear F. *Occlusion in Clinical Practice*. Seattle, WA: The Seattle Institute for Advanced Dental Education; 2000.
- Gibbs C, Lundeen H. *How People Use Their Teeth: Jaw Movement Studies*. Gainesville, FL: University of Florida College of Dentistry; 2003.
- Williamson E. Anterior guidance: Its effect on electromyographic activity of the temporal and masseter muscles. *J Prosthet Dent* 49:816-823, 1983.
- D'Amico A. Functional occlusion of the natural teeth of man. *J Prosthet Dent* 11:899-915, 1961.
- Ciche F, Pinault A. *Esthetics of Anterior Fixed Prosthodontics*. Chicago: Quintessence Publishing Co.; 1994.
- Huntley H. *The Divine Proportion*. New York: Dover Publications, Inc.; 1970.
- Marquardt SR. *Calculated Beauty—Cracking the Code of Beauty's Mystique*. (In press.)
- Kataoka S, Nishimora Y, Saddan A. *Nature's Morphology an Atlas of Tooth Shape & Form*. Chicago: Quintessence Publishing Co.; 2004.
- Okeson JP. *Management of Temporomandibular Disorders of Occlusion*. St. Louis, MO: Mosby; 1974.
- Levy JH. *Occlusion: Underlying mechanisms and clinical applications*. Presentation to the Mid-Atlantic Center for Advanced Dental Study; Chesapeake, VA, October 29, 2004.
- Dawson PE. *Evaluation, Diagnosis, and Treatment of Occlusal Problems*. St. Louis, MO: Mosby; 1974. *AP*

