

BIOLOGY OF OCCLUSION

Robert L. Lee

Chapter 3, "Anterior Guidance"

from the book ADVANCES IN OCCLUSION, POSTGRADUATE DENTAL HANDBOOK SERIES, VOLUME 14.

"Occlusion," by dictionary definition, refers to the act of closure or the state of being closed. In dentistry the word "occlusion" has come to mean the static intercusp relationship of the teeth and also the act of closing the teeth together. This chapter deals primarily with "the act of closure" and how the closing strokes of mastication and other jaw closures are influenced by the anterior teeth (anterior guidance). Anterior guidance refers to both incisal and cuspal guidance. The role of the anterior teeth in the learning process of mastication will also be considered.

Balanced occlusion for natural dentitions has been found to be unphysiological (Stallard and Stuart, 1963),¹ and "unbalanced" or anterior guided occlusion is biologically better (D'Amico, 1958,² Standlee and Caputo, 1979³⁷). Three mechanical guiding factors can prevent posterior teeth from making harmful eccentric contacts. They are the right and left condylar articulations and the appropriate guiding teeth. We are concerned in this chapter with the potentials of the anterior teeth as guiding factors for preventing harmful posterior tooth contacts. These potentials include both mechanical and neuromuscular factors. Since "unbalanced" occlusion is desirable for natural dentitions a question which arises is, how "unbalanced" should a good natural tooth arrangement be? The term "anterior disclusion" is in common use at the present time. Although "anterior disclusion" does not appear in the dictionary, the term is used to describe anterior tooth functions which separate the posterior teeth in eccentric motions of the jaws. The word "disclusion," however, is quantitatively ambiguous and

can be used to mean as little as a few hundredths of a millimeter. Minimal to moderate "lift" on the anterior teeth usually disappears in a relatively short period of time, thus allowing the posterior teeth to come into eccentric contact. The term "anterior disclusion" is inadequate to describe the potential biological guiding function of the anterior teeth. It is also confusing because it implies that bruxing movements are normal. This is evident from observing most present-day illustrations depicting lower cusps moving from centric outward to eccentric position. "Anterior disclusion" also seems to imply that only anterior teeth occlude. Perhaps the best way to "disclude" would be simply to open the mouth.

Anterior teeth have a mechanical advantage over posterior teeth because they are farther from the fulcrum, and this positioning gives them better leverage to offset the closing muscles of mastication. This concept is presented diagrammatically in Figure 3-1. The mechanical advantage is apparent when one tries to "bite hard" with the front teeth as compared to biting hard with the molars. Anterior guidance on a purely mechanical basis, however, is quite limited. Because of their poor axial inclinations, the anterior teeth would no doubt be susceptible to overloading if they were protected only by their mechanical advantage (Figure 3-2). If one assumes that the periodontal structures could withstand the mechanical forces of mastication and that the cuspids were allowed continually to rub against their opposing mates during lateral chewing strokes, these teeth would no doubt be completely worn down at an early age.

The natural crown morphology of both anterior and posterior teeth develops early in life

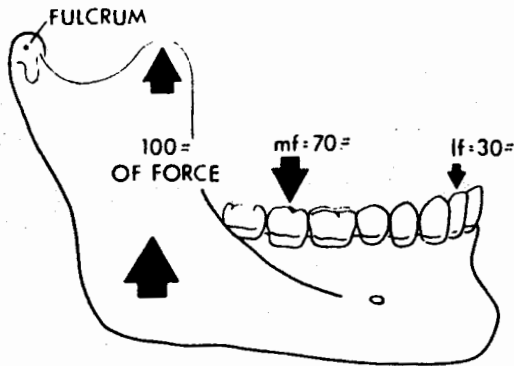


Figure 3-1 A muscle contraction of 100 lb of force (for example) could be distributed more on the posterior teeth (mf) and less force (lf) on the anterior teeth. This is because the anterior teeth are farther from the fulcrum than the posterior teeth, and this gives the anterior teeth a mechanical advantage.

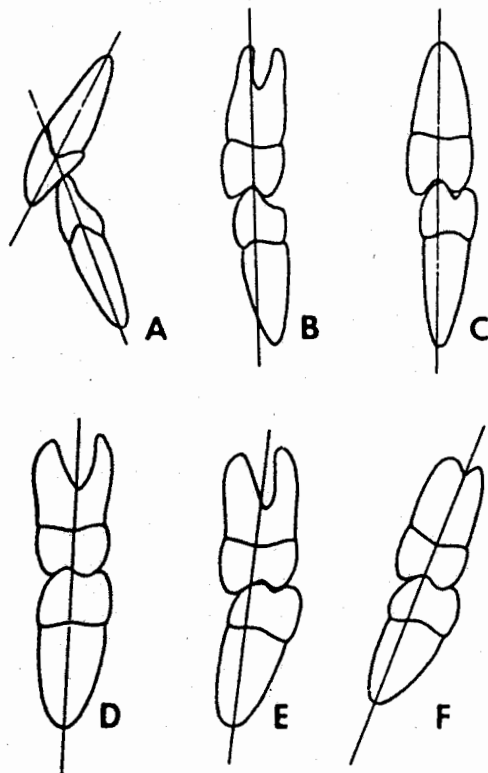


Figure 3-2 The molars and premolars are in axial alignment with their mates in the opposing arch. The anterior teeth (A), however, have poor axial relations to their mates in the opposite arch. Because of keen proprioception and strategic location, the anterior teeth are protected from over-stress when the occlusion is functioning properly.

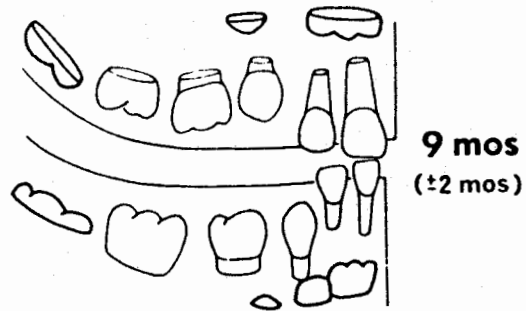

Figure 3-3 By nine months of age, the anterior teeth of the child are erupting into the oral cavity and produce early subconscious awareness of occlusion which is recorded by the central nervous system.

and is complete in every detail prior to tooth eruption into the oral cavity (Figure 3-3). However, the other organs and components of the mouth and related structures continue to change significantly long after the occlusal morphology of the teeth is complete. This morphology does not change except from unnatural causes such as trauma, wear, decay, chemicals, and operative and restorative procedures. Natural tooth morphology per se is not the cause of most malocclusion problems. It is the relationships of the upper teeth to the lower teeth as the jaws close (in function and nonfunction) that create the majority of problems in occlusion. Most of these poor relationships of the teeth are due to skeletal disharmonies connected with heredity, growth and development, and habits. Other bad relationships of the teeth may be caused by lost teeth and subsequent tooth drift, or even by iatrogenic causes such as high crowns and fillings or improper orthodontic treatment.

THE LEARNING PROCESS

Until recently there have been few extensive studies in mandibular neuromuscular physiology. D'Amico (1958)² published his thesis on the canine teeth. Moyers (1956)³ reported on the role of the neuromuscular mechanism and centric relation. With the improvement of instruments and methods during the last twenty years, research in neuromuscular physiology has given new insight in the study and clinical treatment of occlusal problems (Ahlgren, 1969,⁴ Jerge, 1964,⁵ Kawamura, 1967,⁶ and Schärer,

Stallard, and Zander, 1967). A better understanding of the role of the central nervous system and the *learning process* as well as of muscle physiology and proprioception makes it clear that occlusion involves more than mechanics. The muscles have no intelligence of their own and must receive all directional stimuli from the central nervous system. The central nervous system gathers and stores information from many sources, including the teeth.

Ramfjord and Ash (1971)⁸ state that with the growth of the infant and the eruption of the teeth, afferent stimuli from the receptors in the periodontal membrane influence the central nervous system and reflexly influence the position of the mandible. With the eruption of the teeth, the process of mastication is *learned*, and learning depends upon the *cerebral cortex*. In the adult, alterations in tooth position, loss of teeth, high fillings, and other influences evoke learning of new masticatory patterns. In time, these new jaw movements may contribute to dysfunctional states in components of the masticatory system which cannot adapt or compensate for the poor relationships of the teeth.

The first teeth to erupt into the child's mouth are the incisors, which establish early subconscious occlusal awareness (Figure 3-3). As the child becomes an adult the anterior proprioceptive feedback mechanism should continue to keep the central nervous system informed of how the lower teeth approach the upper teeth during the closing motions of the jaws. Perhaps the child learns to chew by trial and error much as he learns to walk or to feed himself. In addition to the periodontal pressoreceptors there are many other organs including the lips, tongue, cheeks, mucosa, skin, and muscles that are rich with proprioceptive bodies. These proprioceptors continuously monitor the position of the mandible and feed the information back to the brain (Figure 3-4). If a person is fortunate enough to develop a good relationship of the teeth, learned reflexes develop by which the mandible functions more vertically as the lower teeth approach the upper in the final portion of the chewing strokes. In lateral chewing strokes, for example, these controlled reflexes allow the lower cuspids to approach their mates in the upper arch and then cause the mandible to swing toward the midline so the cuspids do not clash (Figure 3-5). The avoidance of clashing eccentric contacts between the upper and lower anterior teeth during

Anterior Proprioceptive Feedback

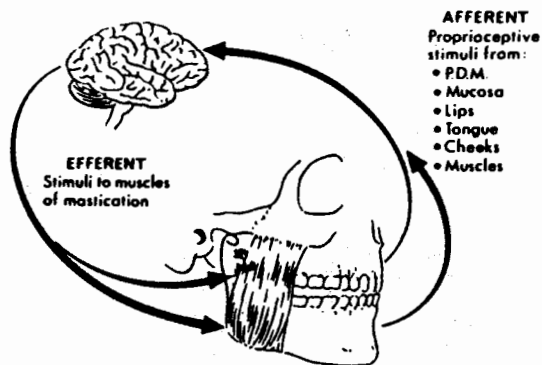


Figure 3-4 In addition to the periodontal pressoreceptors, there are many other organs including the lips, tongue, cheeks, mucosa, skin, and muscles that contain proprioceptive bodies. These proprioceptors continuously monitor the position of the mandible and feed the information back to the brain. The brain, in turn, tells the muscles how to move the mandible.

Frontal Plane Unilateral Chewing Motion

(MANDIBULAR INCISORS)

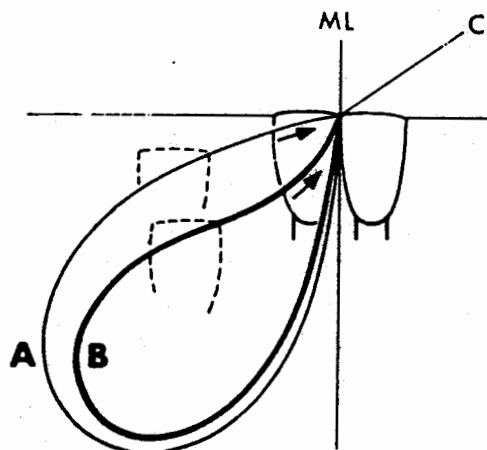
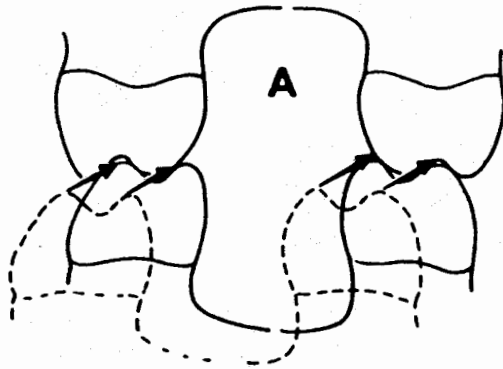


Figure 3-5 Path A illustrates a unilateral chewing stroke on a patient with worn cuspids. These patients chew in a more horizontal manner, which results in continued wear on the teeth. Pathway B shows the effects on the lateral chewing patterns when the cuspids have normal length and position. The patient learns to function more vertically in the final portion of the chewing stroke when the cuspids are functioning properly.

HORIZONTAL CHEWING



VERTICAL CHEWING

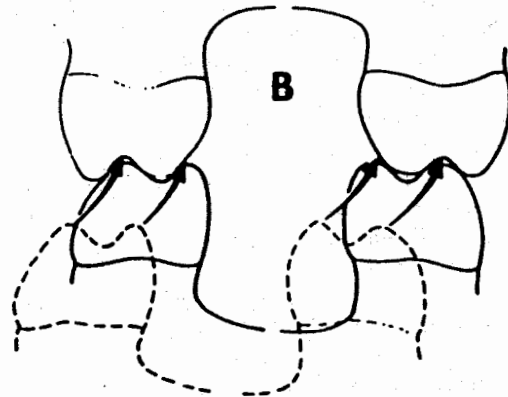


Figure 3-6 Horizontal chewing A results in increased chances of eccentric molar and premolar contacts or abnormal flattening of posterior crowns or restorations. More vertical chewing B results in less wear on the teeth and less stress on supporting tissues provided the guidance to centric position is assigned to the proper anterior teeth. More vertical chewing permits posterior crowns to retain normal occlusal morphology, which has the detailed anatomy of a young unworn dentition. Functional efficiency of pattern B is created by having well-formed cusps, fossae, ridges, and grooves. The occluding functional cusps can penetrate and shred tough fibrous foods and also crush the hard brittle pieces in the fossae.

mastication may be similar to the learned reflex of walking, where the feet pass very close to the floor but seldom touch it. More vertical guidance by the anterior teeth helps to prevent the upper and lower posterior teeth from colliding as the mandible moves toward centric position (Figure 3-6).

The teeth do not have to strike to stimulate the pressure sensitive receptors in the periodontal tissues. The presence of food between the teeth can be detected by pressure on the periodontal pressoreceptors and the information relayed to the brain. Kawamura has shown that the teeth most sensitive to pressure changes are the central incisors, followed by the laterals, cuspids, bicuspid, and last the molars, the most insensitive (Kawamura, Nishiyama, and Funakoshi, 1967).

The author has observed several cases in which young people have used diamond fingernail files to remove cuspid tips in order to have "even teeth." In other cases, people with anterior overjets have simulated end-to-end bites because the person thought that it looked more "normal." Some of these patients developed myofacial pains over a prolonged period. It might be wise to teach children and young people the functions of their teeth and why they should masticate vertically. They can be taught to make conscious efforts to avoid bruxing. The

training of mastication may be compared to training in proper tooth brushing, correct walking habits, or many other learned rational behavior patterns.

CENTRIC POSITION

No doubt the most important condyle-to-menisiscus, arch-to-arch, tooth-to-tooth relationship in occlusion is centric relation position. Centric relation is the ending location of good chewing strokes and is a comfortable physiologic position for all people who have relatively healthy temporomandibular joints and good mandibular muscle control. Centric relation may be defined as any place along the arc of closure where the condyles are bilaterally in their most superior position and in intimate contact with the meniscus in the glenoid fossae when no lateral forces are applied. A stable centric position depends upon bones, ligaments, and muscles which are relatively free from pathology. Maintaining a stable centric position of the condyles can be better assured by having well-related anterior teeth. Centric position of the condyles in the fossae is continuously reinforced by the musculature through good vertical guidance from the anterior teeth.

